

## EXPRESSION OF C-MYC PROTO-ONCOGENE IN PREMALIGNANT AND MALIGNANT UTERINE CERVIX LESIONS

Zoran Protka<sup>1</sup>, Slobodanka Mitrović<sup>2</sup>, Nebojsa Arsenijević<sup>3</sup>, Dejan Baskić<sup>3</sup>, Gordana Radosavljević<sup>3</sup>, Milos Stanković<sup>3</sup>, Goran Lukić<sup>1</sup> and Slobodan Arsenijević<sup>1</sup>

<sup>1</sup>Department of Obstetrics and Gynecology, <sup>2</sup>Department of Pathology, Clinical Center Kragujevac and Medical Faculty University of Kragujevac, <sup>3</sup>Institute of Microbiology and Immunology, Medical Faculty University of Kragujevac, Kragujevac, Serbia

## EKSPRESIJA C-MYC PROTO-ONKOGENA U PREMALIGNIM I MALIGNIM PROMENAMA GRLIĆA MATERICE

Zoran Protka<sup>1</sup>, Slobodanka Mitrović<sup>2</sup>, Nebojsa Arsenijević<sup>3</sup>, Dejan Baskić<sup>3</sup>, Gordana Radosavljević<sup>3</sup>, Miloš Stanković<sup>3</sup>, Goran Lukić<sup>1</sup> i Slobodan Arsenijević<sup>1</sup>

<sup>1</sup>Klinika za Ginekologiju i akušerstvo, <sup>2</sup>Centar za patologiju, Klinički centar Kragujevac i Medicinski fakultet Univerziteta u Kragujevcu  
<sup>3</sup>Institut za Mikrobiologiju i imunologiju, Medicinski fakultet Univerziteta u Kragujevcu, Kragujevac, Srbija

Received/Primljen: 08. 06. 2006. Accepted/Prihvaćen: 19. 03. 2007.

### ABSTRACT

The aim of the study was to assess the expression and clinical significance of C-myc proto-oncogene in the progression of cervical neoplasms.

To establish the role of this proto-oncogene in uterine cervix carcinogenesis, we examined 69 tissue samples of: low grade cervical squamous intraepithelial lesions (SIL) (n=16), high grade SIL (n=11), portio vaginalis uteri (PVU) carcinoma in situ (n=11) and PVU invasive carcinoma, stage IA-IIA (n=13) (study group) and 18 samples without SIL or malignancy (control group), between January 2004 and December 2005. Expression of C-myc was detected immunohistochemically using monoclonal antibodies. Fisher's exact test was used to assess statistical significance. Sensitivity and specificity of the test, are higher and qualify the test as possible screening method for early detection of changes in the uterine cervix.

In our study, overexpression of C-myc oncogene was found only in patients with PVU invasive carcinoma (3/13–23.0%). Significant difference was not found in the frequency of overexpression in patients with PVU invasive carcinoma in relation to the control group (Fisher's test; p=0.064). The method's sensitivity of determining this oncogene with the aim of detecting PVU invasive carcinoma was 23% while specificity was 72.2%. We confirmed in our research that expression of C-myc oncogenes was increased only in patients with PVU invasive carcinoma. However, a more extensive series of samples and additional tests are required to establish prognostic significance of C-myc in cervical carcinogenesis.

**Key words:** C-myc proteins, immunohistochemistry, carcinoma, cervix utery.

### SAŽETAK

Cilj ove studije je da ispita ekspresiju i klinički značaj C-myc proto-onkogen u progresiji cervikalnih neoplazija.

Da bi utvrdili ulogu ovog onkogen u karcinogenezi grlića materice, između januara 2004. i Decembra 2005. ispitivali smo 69 uzoraka tkiva od čega: Low grade SIL (n=16), High grade SIL (n=11), Ca PVU in situ (n=11) i Ca PVU invasivum gradus Ia-IIa (n=13) (eksperimentalna grupa) a 18 uzoraka bez SIL ili malignih promena na grliću materice (kontrolna grupa). Ekspresija C-myc onkogen je utvrđivana imunohistohemijski, korišćenjem monoklonskih antitela. Za ispitivanje statističke značajnosti je korišćen Fisher-ov test (p<0.05). Utvrđivanjem senzitivnosti i specifičnosti testa, nivo pouzdanosti ovih analiza je korišćen kao moguća skrining metoda za ranu detekciju promena na grliću materice.

U našoj studiji pozitivna ekspresija C-myc onkogen je pronađena samo kod pacijentkinja sa Ca PVU invasivum (3/13–23.0%). Analizom učestalosti pozitivne ekspresije C-myc onkogen između kontrolne grupe i pacijentkinja sa Ca PVU invasivum, nije pronađena statistički značajna razlika (p=0.064). Senzitivnost metode određivanja ovog onkogen u cilju dijagnostikovanja invazivnih promena na grliću materice je 23%, a specifičnost 72.2%. U našim istraživanjima smo utvrdili da ekspresija C-myc onkogen je povećana samo kod Ca PVU invasivum.

Potrebne su međutim mnogo veće serije uzoraka da bi se utvrdio prognostički značaj ovog onkogen u karcinogenezi grlića materice.

**KLjučne reči:** C-myc proteini, imunohistohemija, karcinom, grlić materice.

### INTRODUCTION

Carcinogenesis is known to involve aberrant expression of genes involved in cell proliferation and differentiation. In mammalian cells, several independent lines of evidence have implicated the proto-oncogene C-myc in the control of cell proliferation and entry into the cell cycle (1). This gene was discovered as a cellular homologue of the transforming oncogene of avian viruses (2) and its product was subsequently found to be activated in various human cancers, including lung, breast, colon and uterine cervix (3, 4). The theory that C-myc acts as a central oncogenic switch in human cancers has been demonstrated by the ability of the oncogenic viral V-myc gene to induce rapid development of a variety of tumors in infected chickens (5). Chlamydia trachomatis and HPV high-risk types may contribute to neoplastic changes in the transformation of uterine cervix and also might modulate expression of C-myc oncogene (6). The C-myc gene belongs to the myc family that includes B-myc, L-myc, N-myc and S-myc. However, only C-myc,

L-myc and N-myc have neoplastic potential (7). The ability of myc to promote cell proliferation indicates that its de-regulation leads to de-regulated DNA synthesis and genomic instability (8). De-regulated myc expression is linked to increase in both cyclin A and cyclin E levels (9). Many studies demonstrated that poor prognosis is in positive correlation with the expression degree of this oncogene (ovarium, uterus, cervix, lungs, prostate, breast, colon) (10–13). Amplification and/or overexpression of C-myc gene were frequently found in the advanced stages of cervical cancers and were shown to be associated with tumor progression (14, 15) and with aggressive, poorly differentiated phenotype. Moreover, myc overexpression was related to a 6.1 time higher risk of distant metastases suggesting that activation of this proto-oncogene may lead to the greater metastatic ability of tumor cells (16). A different distribution of myc expression has been reported in premalignant SIL lesions. While several studies have demonstrated that higher myc expression was positively related to all stages of pre-can-

cerous lesions (17), others have observed higher levels of this proto-oncogene only in invasive cancers (18).

**PATIENTS AND METHODS**

This prospective study was carried out during 2004 and 2005, at the Department of Obstetrics and Gynecology, Faculty of Medicine and the experimental part was performed at the Laboratory for Experimental and Clinical Immunology of the Faculty of Medicine and at the Immunological Laboratory of the Public Health Institute, Kragujevac.

In patients operated at the Department of Obstetrics and Gynecology because of premalignant and/or malignant changes of the uterine cervix, some tissue sections were taken from the operative material (hysterectomy, punch biopsy or conization) for pathological verification and used for this research.

The control group consisted of 18 patients in whom ambulatory biopsy of the uterine cervix was performed (Papanicolaou test was indicated) and where malignant changes or SIL were not found by histopathology (cervicitis chronica of mild to moderate degree).

The study group consisted of 16 patients with pathological diagnosis of low grade SIL, 11 with high grade SIL, 11 with PVU carcinoma in situ and 13 with PVU invasive carcinoma, stage IA-IIA.

C-myc oncogene expression was followed in patients and control group.

Criostat sections were sent for intraoperative diagnosis. Extra sections of cervical lesions were snap-frozen in liquid nitrogen and stored at -70°C until used in immunohistochemistry.

C-myc (clone 100, Calbiochem, Oncogene Research, Cambridge, USA) monoclonal antibody was used, which was diluted with phosphate buffered saline (PBS, pH 7,2).

Four-micrometer frozen sections were fixed in 100% acetone for 5 minutes and the endogenous peroxidase activity was quenched by 10 minutes incubation in 0,5% hydrogen peroxide. For monoclonal antibody C-myc (concentration 10 µg/ml) incubation with primary antibody was carried overnight at 4°C.

Sections of C-myc positive lung carcinoma were used as positive controls. For negative controls, the samples were taken through the procedure with omission of primary antibody.

Slides were evaluated by two of the authors, unaware of immunohistochemical or clinical data by using a semi-quantitative method on a Zeiss AXIOSKOP 2 light microscope. The percentage of immunopositive cells in representative areas of the sections was assessed. The intensity of immunostaining was divided into four categories, namely: negative -(0-5%); 1+ (5-25%), and positive 2+ (25-50%); 3+ (50-100%).

Sections of tissue from the operative material or bioptic material were taken after obtaining the informed consent of patients in accordance with the Declaration of Helsinki and recommendations of the World Health Organization (WHO) for experiments on human material

and after getting the approval of the Ethics Committee no.: 01-4885.

Differences between groups were considered significant (Fisher's exact test) at p<0.05. By establishing sensitivity and specificity of the test, the level of reliability of these analyses was determined as a possible screening method for early detection of changes in the uterine cervix.

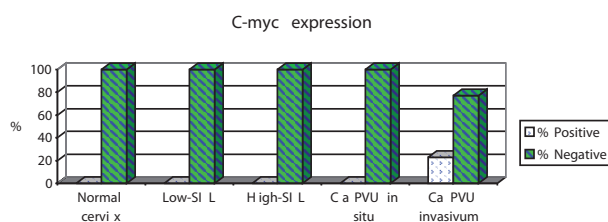
Statistics: based on the frequency of the lesions found, patients were split into 4 subgroups and 2x2 contingency tables were formed. Specificity and sensitivity were calculated. Also, based on the ROC (receiver operating characteristic) curve which represents the relation between specificity and sensitivity, the discrimination power of the test was determined. Differences between groups were considered significant (Fisher's exact test) at p<0.05. On the basis of sensitivity and specificity of the test, these analyses carried become possible screening method for early detection of changes in the uterine cervix.

**RESULTS**

Table 1 and Figure 1 show expression levels of C-myc oncogene in the control and in the experimental group. Overexpression of C-myc oncogene was found only in patients with PVU invasive carcinoma (3/13-23.0%).

**Table 1.** Expression of C-myc in the control and experimental group.

Expression of C-myc	Normal cervix	Low grade SIL	High grade SIL	PVU in situ carcinoma	PVU invasive carcinoma
Negative (-) (N-%)	14/18-77.8%	12/16-75%	8/11-72.8%	9/11-81.9%	6/13-46.2%
Negative (1+) (N-%)	4/18-22.2%	4/16-25%	3/11-27.2%	2/11-18.1%	4/13-30.8%
Positive (2+) (N-%)	0/18-0%	0/16-0%	0/11-0%	0/11-0%	1/13-7.7%
Positive (3+) (N-%)	0/18-0%	0/16-0%	0/11-0%	0/11-0%	2/13-15.3%



**Figure 1.** Percentage of positive and negative C-myc expressions.

Analysis of frequency of patients with positive findings of C-myc oncogene, revealed no statistical differences (p=0.064) when control and PVU invasive carcinoma groups were evaluated. None of the control patients exhibit overexpression of C-myc, while 23% of the patients with PVU invasive carcinoma showed overexpression of C-myc oncogene.

The method's sensitivity of determining this oncogene with the aim of detecting PVU invasive carcinoma was 23% while specificity was 72.2%. On the basis of the frequency of patients with C-myc overexpression, a 2x2 table of contingency was formed, from which sensitivity and specificity were calculated (Table 2).

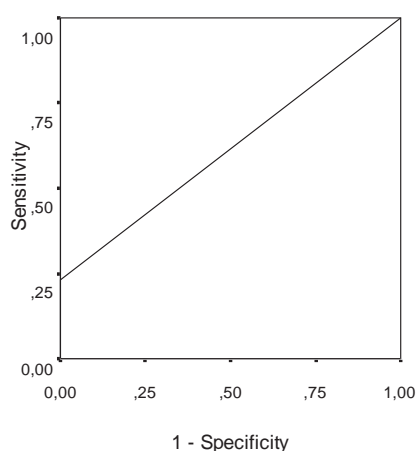
**Table 2.** C-myc expression pattern (PVU invasive carcinoma).

Test	Disease present	Disease absent	Total
C-myc overexpression	3	0	3
C-myc negative	10	18	28
Total	13	18	31

\* patients with PVU invasive carcinoma

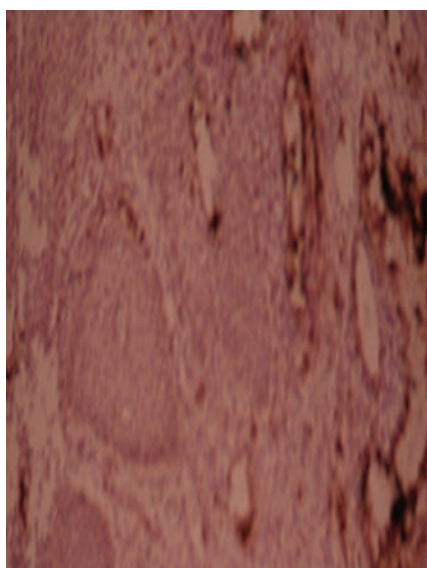
\*\* patients with normal cervix

On the basis of the obtained values of sensitivity and specificity, discrimination power of negative expression in patients with normal findings in the cervix was greater than discrimination power of overexpression of this oncogene, with the aim of determining the existence of change of this type (Figure 2).

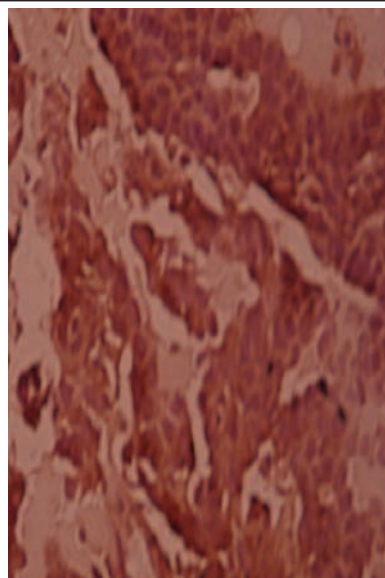


**Figure 2.** ROC (receiver operating characteristic) curve for over-expression of C-myc oncogene in patients with PVU invasive carcinoma.

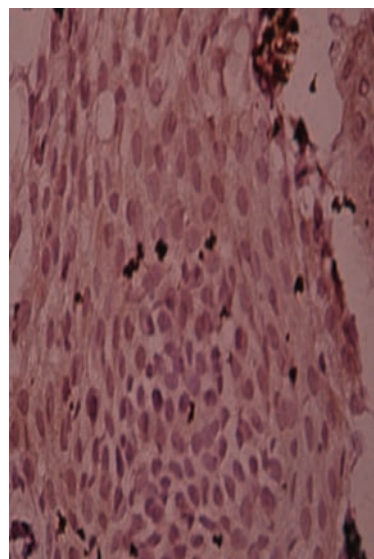
The positive predictive value was 100% which, speaking in statistical terms, means that PVU invasive carcinoma may be expected in all patients with overexpression of C-myc. The negative predictive value was 64.34%, implying that at this percentage of patients with negative expression of C-myc oncogene, the existence of this type of change is not expected.



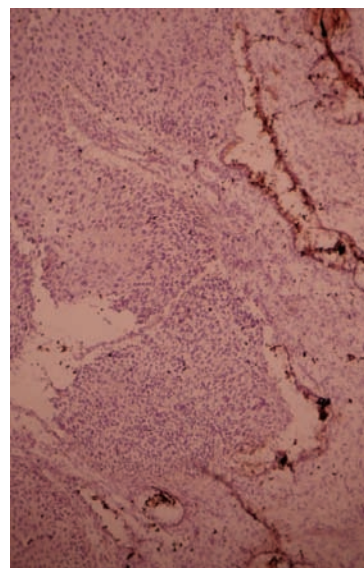
**Figure 3.** Over-expression (1+) of C-myc in Low-grade SIL (40x).



**Figure 4.** Over-expression (3+) of C-myc in Ca PVU invasivum (40x).



**Figure 5.** Over-expression (1+) of C-myc in High-grade SIL (40x).



**Figure 6.** Over-expression (1+) of C-myc in Ca PVU in situ (40x).

## DISCUSSION

This study evaluated expression of C-myc oncogene in a range of tissues obtained from normal, dysplastic and neoplastic conditions of the cervical mucosa, in an attempt to elucidate the expression of this oncoprotein in uterine cervix premalignant and malignant lesions.

C-myc is oncogene that have been investigated for prognostic merit in various malignancies, including carcinoma of the cervix. Up to now, conflicting results were obtained.

C-myc has been shown in some studies to be an independent predictor of poor prognosis in carcinoma of the cervix (19–20). On the other hand, other studies have not revealed significant correlation with adverse outcome (21–22).

Conflicting results have also been published on the prognostic significance of these oncogenes in other gynecological sites (23–24).

Myc protein is widely distributed in different tissues and is predominantly localised in nuclei of cells where its positivity related to proliferation rate. The conflicting results might be due to differences in institutional treatment standards and due to different subjective interpretations of staining intensity and distribution between centers. Because staining is judged on a continuum, differences in institutional „cut-off“ for positive staining may also affect correlation with clinical and pathological results.

Evan et al. (25) found that de-regulated C-myc oncoprotein expression in cervical epithelium may be an initial stage in the progression of lesion through dysplasias towards carcinoma. This event can occur very early in tumorigenesis and may vary to different degrees of the pre-malignant stages.

## REFERENCES

1. Kaczmarek L, Miller MR, Hammond RA, et al. A microinjected monoclonal antibody against human DNA polymerase- $\alpha$  inhibits DNA replication in human, hamster and mouse cell lines. *J Biol Chem* 1986; 261: 10802–7.
2. Kim HS, Shin JY, Zun JY, et al. Immortalization of human embryonic fibroblasts by overexpression of c-myc and simian virus 40 large T antigen. *Exp Mol Med* 2001; 33: 293–8.
3. Abdil EA, Rey A, Duvillard P. Expression of heat shock protein 70 and c-myc in cervical carcinoma. *Anticancer Res* 1998; 18: 1955–6.
4. Evan G, Lewis GK, Ramsay G, Bishop JM. Isolation of monoclonal antibodies specific for human c-myc protooncogene product. *Mol Cell Biol* 1985; 5: 3610–6.
5. Evan GI, Littkewood TD. The role of c-myc in cell growth. *Curr Opin Genet Dev* 1993; 3: 44–9.
6. Schlott T, Eiffert H, Bohnew W, et al. Chlamydia trachomatis modulates expression of tumor suppressor gene caveolin-1 and oncogene C-myc in the transformation zone of non-neoplastic cervical tissue. *Gynecol Oncol* 2005; 98: 409–19.
7. Jansen-Durr P, Meichle A, Steiner P, et al. Differential modulation of cyclin gene expression by Myc. *Proc Natl Acad Sci USA* 1993; 90: 3685–9.
8. Lee L, Dolde C, Barrett J, et al. A link between c-Myc-mediated transcriptional repression and neoplastic transformation. *J Clin Invest* 1996; 97: 1687–95.
9. Loke S, Neckers LM, Schwab G, Jafar ES. C-myc protein in normal tissue. *Am J Pathology* 1988; 131: 29–37.
10. Meichle A, Philipp A, Eilers M. The function of Myc protein. *Biochem Biophys Acta* 1992; 114: 129–46.

Alarcon et al. (26) in their analysis of 72 patients with cervical invasive carcinomas grade I-IIa found that increased expression of C-myc correlated with a worse prognosis.

In our study, overexpression of C-myc oncogene was found only in patients with PVU invasive carcinoma (3/13–23.0%). Analysis of frequency of patients with positive findings of C-myc, revealed no significant differences ( $p=0.064$ ) when control and PVU invasive carcinoma groups were evaluated. The method's sensitivity of determining this oncogene with the aim of detecting PVU invasive carcinoma was 23% and specificity was 72.2%. On the basis of the obtained values of sensitivity and specificity, discrimination power of negative expression in patients with normal findings in the cervix was greater than discrimination power of overexpression of this oncogene with the aim of determining the existence of change of this type. On the basis of high predictive values, it can be concluded, speaking in statistical terms, that all patients with overexpression of C-myc oncogene will have PVU invasive carcinoma.

However, the substantiation of the claim needs much more extensive research.

The findings presented in this study indicate that the evaluation of C-myc expression may provide additional and independent prognostic information to predict the clinical course of the cervical cancer.

Positive expression of this oncogene suggests with great certainty that there are invasive malignant changes in uterine cervix.

However, new studies and additional tests are required to establish the prognostic significance of C-myc in cervical carcinogenesis.

11. Nair SA, Nair MB, Jayaprakash PG, et al. Ras and c-myc oncoproteins during tumor progression in uterine cervix. *Tumori* 1998; 84: 583–8.
12. Ngan HY, Liu SS, Yu H, et al. Proto-oncogenes and p53 protein expression in normal cervical stratified squamous epithelium and cervical intra-epithelial neoplasia. *Eur J Cancer* 1999; 35: 1546–50.
13. Pelengaris S, Khan M, Evan G. Suppressor of Myc-induced apoptosis in beta-cells exposes multiple oncogenic properties of Myc and triggers cancerogenic progression. *Cell* 2002; 109: 321–34.
14. Pelengaris S, Khan M, Evan G. C-myc: more than just a matter of life and death. *Nature Reviews Cancer* 2002; 7: 764–75.
15. Penn LZ, Brooks MW, Laufer EM, Land H. Negative autoregulations of c-myc transcription. *EMBO J*, 1990; 9: 1113–21.
16. Riou GE, Bourhis J, Le MG. The c-myc proto-oncogene in invasive carcinomas of the uterine cervix: clinical relevance of overexpression in early stages of the cancer. *Anticancer Res* 1990; 10: 1225–31.
17. Shii Y, Donohoe S, Yi EC, et al. Quantitative proteomic analysis of Myc oncoprotein function. *EMBO J* 2002; 21: 5088–96.
18. Sowania A, Ong G, Dische S, et al. C-myc oncogene expression and clinical outcome in carcinoma of cervix. *Mol Cell Probes* 1989; 3: 117–23.
19. Zur H. Human papillomaviruses in the pathogenesis of anogenital cancer. *Virology* 1991; 184: 9–13.
20. Dellas A, Torhost J, Gaudenz R, et al. DNA copy number changes in cervical adenocarcinoma. *Clin Cancer Res* 2003; 9: 2985–91.
21. Kohler M, Janz I, Wintzer HO, et al. The expression of EGF receptors, EGF-like factors and c-myc in ovarian and cervical carcinomas and their potential clinical significance. *Anticancer Res* 1989; 12: 1537–47.

22. Kihana T, Tsuda H, Teshima S, et al. Prognostic significance of the overexpression of C-erbB-2 protein in adenocarcinoma of the uterine cervix. *Cancer* 1994; 73: 148–53.
23. Kersemaekers M, Fleuren GJ, Kenter GG, et al. Oncogene alterations in carcinomas of the uterine cervix: overexpression of the epidermal growth factor receptor is associated with poor prognosis. *Clin Cancer Res* 1999; 9: 577–86.
24. Zindy F, Eischen CM, Randle DH, et al. Myc signaling via the ARF tumor suppressor regulates p53-dependent apoptosis and immortalization. *Genes Dev* 1998; 12: 2424.
25. Evan GI, Wyllie AH, Gilbert CS, et al. Induction of apoptosis in fibroblasts by c-myc protein. *Cell* 1992; 69: 119–21.
26. Alarcon RM, Rupnow BA, Graeber TG, et al. Modulation of c-myc activity and apoptosis in vivo. *Cancer Res* 1996; 56: 4315–19.